

Anthocyanin Extracted from Black Soybean Reduces Prostate Weight and Promotes Apoptosis in the Prostatic Hyperplasia-Induced Rat Model

HOON JANG, U-SYN HA, SU-JIN KIM, BYUNG-IL YOON, DONG-SEOK HAN,
SEUNG-MO YUK, AND SAE-WOONG KIM*

Department of Urology, The Catholic University of Korea College of Medicine, Seoul, Korea

Anthocyanin is a natural plant pigment and potent antioxidant. This study was designed to investigate the effects of anthocyanin extracted from black soybeans on a rat model of benign prostatic hyperplasia (BPH), a disease associated with the geriatric population. Thirty male rats were divided into five experimental groups: a control group, a BPH-induced group, and three BPH-induced groups that received oral doses of anthocyanin (40, 80, and 160 mg/kg). Prostate hyperplasia was induced by the administration of testosterone propionate for 4 weeks. Following BPH induction, the anthocyanin-treated groups received the compound for 4 weeks. After anthocyanin treatment, the prostates from the rats in all groups were removed, weighed, and subjected to histological examination. Apoptosis in the prostates was measured by the TUNEL assay. The mean prostate weight for the control animals was 674.17 ± 28.24 mg, whereas the BPH-induced rats had a mean prostate weight of 1098.33 ± 131.31 mg. The mean prostate weights for the rats receiving 40, 80, and 160 mg/kg anthocyanin were 323.00 ± 22.41 , 324.00 ± 26.80 , and 617.50 ± 31.08 mg, respectively. The average prostate weight in the BPH-induced group was significantly higher than in the control group ($p < 0.05$), whereas the prostate weights in the anthocyanin-administered groups were significantly lower than in the BPH-induced group ($p < 0.05$). Injected testosterone led to prostatic hyperplasia as observed histologically, but anthocyanin administration helped to prevent this change. Apoptotic body counts were significantly higher in groups receiving anthocyanin than in the BPH-induced group ($p < 0.05$). These results suggest that anthocyanin may be effective in decreasing the volume and suppressing the proliferation of the prostate. Further studies are needed to better understand the mechanisms and actions of anthocyanin, and these studies may lead to the clinical application of anthocyanin in treating BPH.

KEYWORDS: Anthocyanin; antioxidant; apoptosis

INTRODUCTION

Free radicals naturally generated in the human body through metabolic processes induce oxidative injury to cellular components such as proteins, DNA, and lipids. This is thought to result in the loss of cellular and tissue function that is behind the mechanism of aging (1–3). Benign prostatic hyperplasia (BPH) is a disease that has a high incidence among elderly males (4, 5), and aging and the presence of testis are known as risk factors for BPH (6). The molecular biological mechanisms influencing the etiology of BPH have not yet been elucidated. However, the oxidative stress-mediated mechanism that is thought to be a cause of aging is believed to also be associated with prostate cell hyperproliferation and tissue deformity. Consequently, it is hypothesized that antioxidant reactions that inhibit the generation of or remove free radicals may prevent aging (7) as well as suppress the progression of BPH.

*Address correspondence to this author at the Catholic University of Korea Seoul, St. Mary's Hospital, 505 Banpo-Dong Seocho-Gu, Seoul 137-701, Korea (phone 82-2-2258-1071; fax 82-2-2258-1080; e-mail ksw1227@catholic.ac.kr).

Anthocyanin is a water-soluble natural pigment that appears as red, purple, and blue in plants and belongs to the flavonoid parent class of molecules. It has been shown to mediate antioxidant reactions by stabilizing or inactivating free radicals and preventing cellular oxidative stress (8, 9). To examine the potential therapeutic role of anthocyanin in treating BPH, we extracted anthocyanin from black soybeans and administered the extract to rats with induced prostatic hyperplasia. Prostate weight, the pattern of histological changes, and the number of apoptotic cells were then examined and compared.

MATERIALS AND METHODS

Preparation of Anthocyanin. The anthocyanin used in our experiment was from the Rural Development Administration, Suwon, Republic of Korea. The anthocyanin was extracted by use of the following method. Hand-peeled seed coats (500 g) from Cheongja 3 black soybeans were extracted twice with 2000 mL of 80% ethanol (0.1% acetic acid) for 2 days at 4 °C, in the dark. The solution was then filtered through a 0.45 μ m filter and concentrated in a rotary evaporator (35 °C) to obtain the crude anthocyanin extract. The residual solvent was removed from the crude extract by freeze-drying, and the resulting red powder was stored at –70 °C.

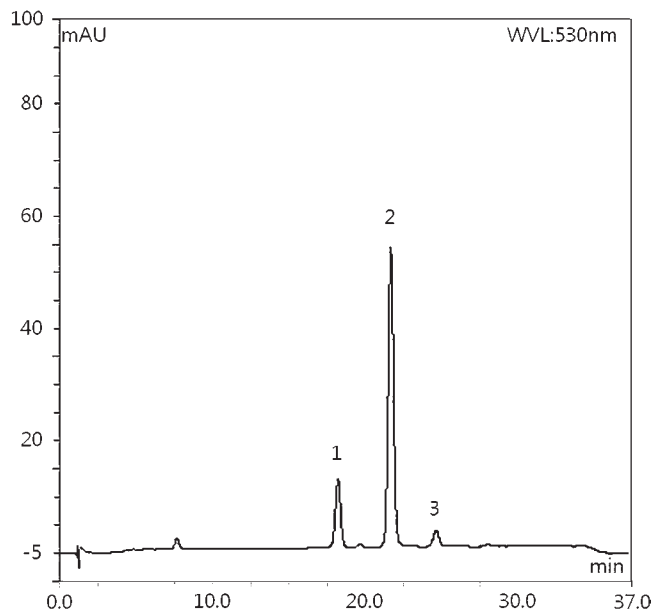


Figure 1. HPLC chromatogram of anthocyanin crude extract from black soybean (Chengja 3). Peaks: 1, delphinidin-3-*O*-glucoside; 2, cyanidin-3-*O*-glucoside; 3, petunidin-3-*O*-glucoside.

This powder was dissolved in distilled water and administered to the rats according to the animals' weights at concentrations of 40, 80, and 160 mg/kg. The appropriate amount of anthocyanin was added to the animals' water bottles every day (250 mL), and the rats were allowed to drink freely.

Analysis of Total and Individual Anthocyanin Contents. High-performance liquid chromatography (HPLC) was performed by using a Dionex Ultimate 3000 series (Dionex Softron GmbH, Germering, Germany) dual low-pressure ternary gradient pump and Ultimate 3000 series photodiode array detector (PDA) for anthocyanin analysis. The crude anthocyanin extract was analyzed by HPLC chromatogram (Figure 1). Three principal anthocyanin peaks were detected in the chromatogram by diode array detection (DAD) at 530 nm. Major peaks 1, 2, and 3 were identified as delphinidin-3-*O*-glucoside, cyanidin-3-*O*-glucoside, and petunidin-3-*O*-glucoside, respectively, by comparison with the HPLC retention times of our standard compounds. The proportion of each anthocyanin is shown in Table 1.

Experimental Animals and Maintenance Conditions. Experimental animals were 12-week-old Sprague–Dawley male rats weighing 380–400 g and were supplied by Samtaco Bio Co. (Osan, Korea). After a 1 week adjustment period, the animals were housed in pairs in plastic cages. The rats were maintained on a 12 h light/12 h dark cycle in rooms that were kept at 18–23 °C and 40–60% humidity. Animals were fed ad libitum. This study was approved by the Institutional Animal Care and Use Committee (IACUC) of the Catholic University of Korea, Seoul St. Mary's Hospital (IRB approval no. CUMC-2010-0106-02).

Orchiectomy. To prevent the influence of intrinsic testosterone, rats in all groups except the control group underwent bilateral orchiectomies performed 3 days prior to the administration of testosterone propionate. For the orchiectomies, the animals were anesthetized by intraperitoneal injections of ketamine (0.05 mL/kg) and xylazine (0.05 mL/kg). The testis was exposed by performing a transverse resection on both scrota in the supine position, and the spermatic cord and blood vessels were ligated with 3-0 sutures and resected.

Induction of BPH. Animals were randomly divided into the control group ($n = 6$) and the BPH-induced group ($n = 6$). Prostatic hyperplasia was induced in the BPH-induced group by daily subcutaneous injections of testosterone propionate (3 mg/kg, Sam Il Pharmaceuticals, Seoul, Korea) for 4 weeks. An additional 4 weeks after BPH induction, the control and the BPH-induced groups were anesthetized with ketamine (75 mL/kg) and xylazine (12 mL/kg). The entire prostate was removed from all animals. Each prostate was weighed and prepared for pathohistological testing.

Anthocyanin Administration Groups. The effects of anthocyanin were tested in a total of 18 rats. Prostatic hyperplasia was induced in all

Table 1. Total and Individual Anthocyanin Contents of Black Soybean

cultivar	anthocyanin contents ^a (μg/g)			
	Dp3glc	Cy3glc	Pt3glc	total
Cheongja 3	3049.0	8277.2	791.7	12117.9
% of total	25.2	68.3	6.5	100

^aDp3glc, delphinidin-3-*O*-glucoside; Cy3glc, cyanidin-3-*O*-glucoside; Pt3glc, petunidin-3-*O*-glucoside.

animals by daily subcutaneous injections of testosterone propionate (3 mg/kg, Sam Il Pharmaceuticals) for 4 weeks. Following the induction of prostatic hyperplasia, the animals were randomly divided into three groups of six and given oral doses of anthocyanin diluted in distilled water at various concentrations for 4 weeks. The first group ($n = 6$) received 40 mg/kg of anthocyanin, the second group ($n = 6$) received 80 mg/kg, and the third group ($n = 6$) was given 160 mg/kg.

Collection of Prostate Tissues and Pathohistological Tests. Following BPH induction and subsequent anthocyanin administration, the rats from all groups were anesthetized and the prostate from each animal was removed. All prostates were weighed, and sections of the prostate tissue were fixed in a 10% formalin solution, embedded in paraffin, and then stained with hematoxylin and eosin according to the standard protocol. The stained prostate tissue sections were examined under light microscopy for histological changes to prostatic epithelial cells and matrix.

Terminal Deoxynucleotidyl Transferase (Tdt) Mediated dUTP Nick End Labeling (TUNEL) Assay. To assess apoptosis in the extracted prostate tissues, a TUNEL assay was performed by Apop Tag *In Situ* Apoptosis Detection Kits (Millipore, Billerica, MA). To perform the TUNEL assay on prostate tissues, tissues embedded in paraffin were first prepared as sections 5 μm in thickness, deparaffinized by treating with xylene for 5 min three times, treated with 100% ethanol for 2 min twice, and subsequently rehydrated by treating with 95% ethanol once and 70% ethanol once for 3 min each wash. The rehydrated sections were washed with PBS for 5 min, incubated with proteinase K for 15 min, and washed twice with deionized water (dH₂O) for 2 min. To neutralize intracellular peroxidase, the washed sections were immersed in 3% H₂O₂ for 5 min at room temperature and washed twice with PBS. An amount of 75 μL/5 cm² of an equilibration buffer was added to the washed sections and allowed to incubate for at least 10 s and was then gently tapped off and carefully blotted around the section. Then the tissue sections were incubated in 55 μL/5 cm² of Tdt for 1 h at 37 °C. Following the Tdt incubation, the sections were washed three times with PBS and then incubated with an antidigoxigenin conjugate for 30 min. After the incubation with the conjugate, the sections were washed with PBS. Diaminobenzidine (DAB) staining was performed for 6 min at room temperature, and the sections were washed with dH₂O. Prostate tissue sections were also stained with hematoxylin and eosin and examined under light microscopy.

Evaluation of Apoptosis in Prostate Tissues. To evaluate apoptosis in the prostate tissues, the number of cells shown to be positive for the TUNEL assay was assessed, and the numbers were compared among the groups. To determine the number of cells positive for the TUNEL assay, five areas of the slide of each group were selected at random, and the cells were counted under light microscopy at 400× magnification.

Data Analysis. The volume of the prostate is presented as a mean ± standard deviation, and statistical analysis was performed by use of the SPSS for Microsoft Windows program (ver. 12.0). Statistical analysis was by the Kruskal–Wallis test and Mann–Whitney U test. For comparisons among the groups, Tukey's test was performed, and p values of < 0.05 were considered to be statistically significant.

RESULTS

Mean Prostate Weight of BPH-Induced and Anthocyanin Administration Group. At 8 weeks, the mean prostate weight of the control group was 674.17 ± 28.24 mg. The mean prostate weight of the group that underwent induced prostatic hyperplasia by testosterone injection was 1098.33 ± 131.31 mg, which was significantly higher than that of the control group ($p < 0.05$). The mean prostate weight of the rats that received 40 mg/kg anthocyanin was 323.00 ± 22.41 mg, that of the rats that received

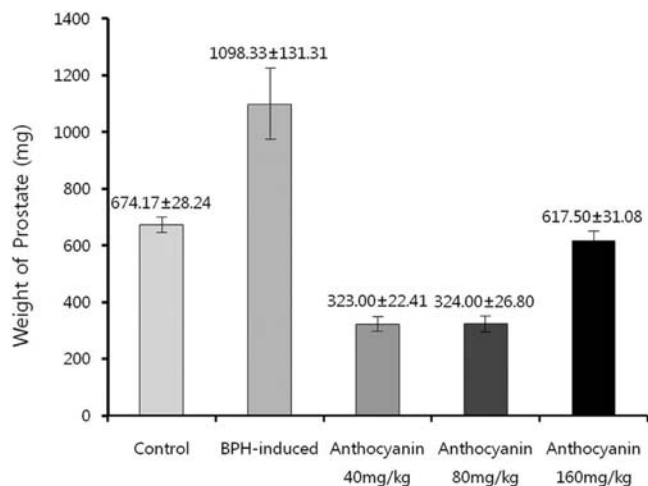


Figure 2. Mean weight of prostate specimens from rats in the control group, benign prostatic hyperplasia (BPH)-induced group, and anthocyanin-administered groups. Prostate weight was higher in the BPH-induced group than in the control group and lower in the anthocyanin-administered groups than in the BPH-induced group.

80 mg/kg anthocyanin was 324.00 ± 26.80 mg, and that of the rats that received 160 mg/kg anthocyanin was 617.50 ± 31.08 mg. Compared with the control and the prostatic hyperplasia-induced groups, administration of anthocyanin led to a significant reduction in prostate weight ($p < 0.05$) (Figure 2).

Pathohistological Findings. In the control group, one layer of low columnar epithelial cells formed secretory lumen, and the lumen was filled with thin acidophilic materials. Undeveloped epithelial cells forming the prostate gland were arranged as a single layer. In contrast, the epithelial cells were arranged as several uneven layers in the prostatic hyperplasia-induced group, and the gland was developed excessively. Additionally, the number of glands was 2–3 times the number in the control group. In groups that received anthocyanin, columnar epithelial cells were arranged as multiple layers, and the proliferation of epithelial cells and the number of glands were increased compared with the normal group. However, in comparison with the prostatic hyperplasia-induced group, prostate cell proliferation and the development of glands were noticeably decreased (Figure 3).

Apoptosis in Prostate Tissues. Cells undergoing apoptosis (positive cells) form apoptotic bodies and appear black or dark brown in the TUNEL assay (Figure 4). The number of positive cells in the control group was 3.67 ± 0.86 , and that in the prostatic

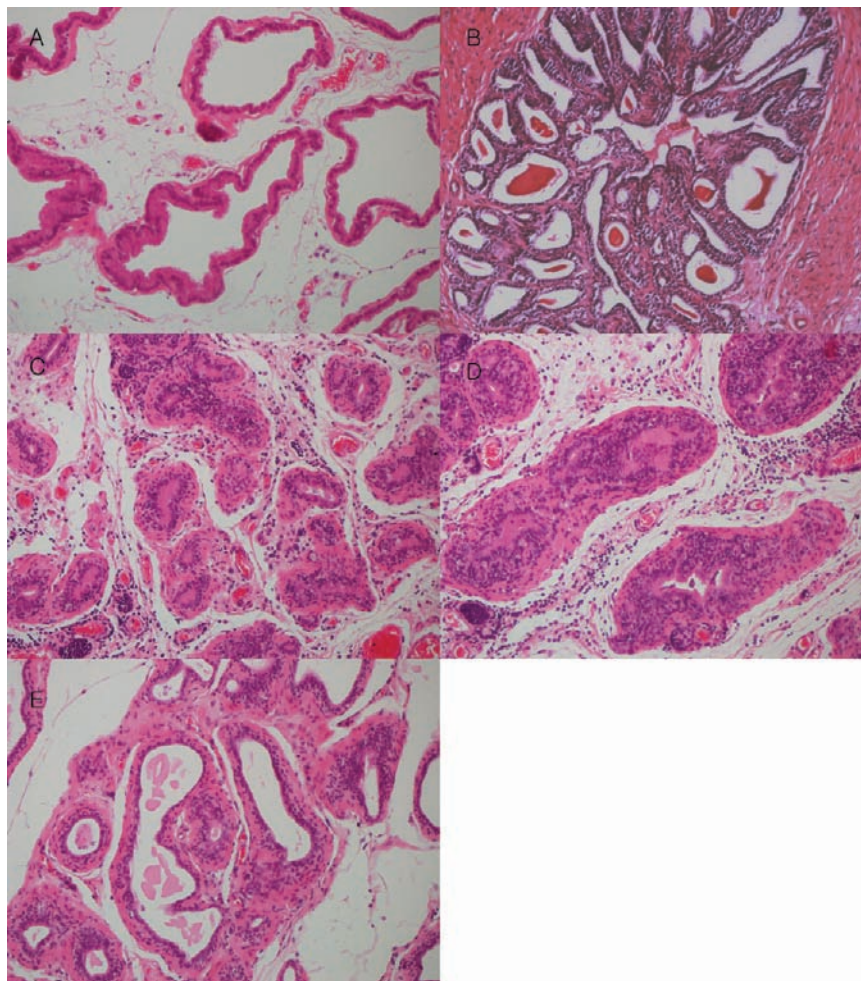


Figure 3. Histologic findings from prostate specimens in the rat model of benign prostatic hyperplasia (BPH): (A) secretory luminal cells, lined with a single layer of low columnar epithelium, and the acinus filled with pale eosinophilic material in the control group (H&E, $\times 200$); (B) larger glandular nodule with focus of stromal hyperplasia [tangent ducts bordering the nodule show epithelial hypertrophy and the formation of new gland branches and severe fibrovascular stromal thickening in the BPH-induced group (H&E, $\times 200$)]; (C–E) restricted proliferation of columnar epithelial cells, limited development of the gland, and absence of stromal connective tissue proliferation in the anthocyanin-administered groups. A, control group; B, BPH-induced group; C, anthocyanin 40 mg/kg administered group; D, anthocyanin 80 mg/kg administered group; E, anthocyanin 160 mg/kg administered group.

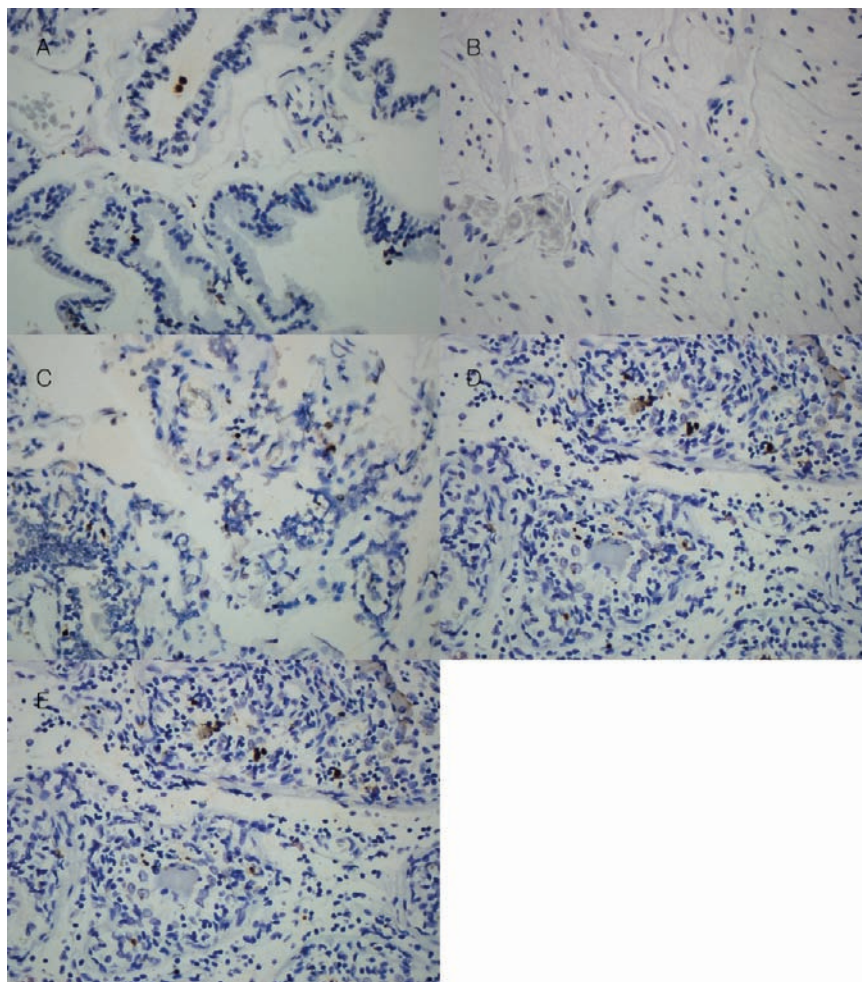


Figure 4. Histologic findings of the TUNEL assay in specimens from each group. Cells undergoing apoptosis, called apoptotic bodies, show as black or dark brown in the TUNEL assay. (A) A few positive TUNEL cells were identified in the control group (TUNEL, $\times 400$); (B) no positive TUNEL cells were identified in the BPH-induced group (TUNEL, $\times 400$); (C–E) several positive TUNEL cells were identified in the anthocyanin-administered groups, especially the group administered 80 mg/kg anthocyanin (D) (TUNEL, $\times 400$). A, control group; B, BPH-induced group; C, anthocyanin 40 mg/kg administered group; D, anthocyanin 80 mg/kg administered group; E, anthocyanin 160 mg/kg administered group.

hyperplasia-induced group was 1 ± 0.94 . The numbers of positive cells in the groups administered anthocyanin were 15.67 ± 2.36 (40 mg/kg), 28.33 ± 1.71 (80 mg/kg), and 11.00 ± 0.66 (160 mg/kg). Compared with the control and the prostatic hyperplasia-induced group, administration of anthocyanin resulted in a significantly higher number of apoptotic cells (Figure 5).

DISCUSSION

We speculate that with aging, oxidative stress in the human body is increased, and when oxidative injuries caused by free radicals cannot be prevented by the antioxidant system, aging occurs (10). We hypothesize that a similar aging process occurs in the prostate that induces prostatic hyperplasia. In addition, we believe that when oxidative stress accumulates and protection by endogenous antioxidants is not sufficient for maintaining optimal cellular function, it is necessary to supply exogenous antioxidants (11) to help protect the human body from oxidative injury and possibly suppress the progression of aging. Simultaneously, we speculated that administration of exogenous antioxidants may also be effective at inhibiting or preventing BPH.

We used a rat model to examine the effect of anthocyanin, a plant-derived antioxidant, on the progression of induced prostatic hyperplasia. Our results demonstrated that prostate weight and pathohistological changes associated with prostatic hyperplasia

were significantly reduced by the administration of anthocyanin. We also observed that apoptosis in the prostate tissues was increased following the administration of anthocyanin. However, the reduction of prostate weight and increased apoptosis were not necessarily proportional to the increased dose of anthocyanin.

The reduction of prostate weight and increase of apoptosis after the administration of anthocyanin observed in our study could be due to various physiological and chemical reactions of anthocyanin. Wang et al. (12) reported that antioxidant reactions of anthocyanin leading to the removal of superoxide (O_2^-), singlet oxygen (1O_2), peroxide (O_2^{2-}), hydrogen peroxide (H_2O_2), and hydroxyl radical (OH^\bullet) are mediated by the phenolic structure of anthocyanin. Shih et al. (13) reported that anthocyanin-accelerated antioxidant response element (ARE)-regulated phase II enzyme activity is important for the protection of normal cells from oxidative stress. In addition, several *in vitro* studies in cancer cells demonstrated that anthocyanin has antiproliferative activity by potentially inhibiting cell cycle control proteins such as p53, p21, p27, cyclin D1, and cyclin A at various points in the cell cycle (14–19).

It has been shown that anthocyanin is involved in apoptosis, which plays an important role in the growth and development of normal cells. In several studies, a pro-apoptotic effect of anthocyanin on diverse cells was shown (15, 16, 20–23) and has been

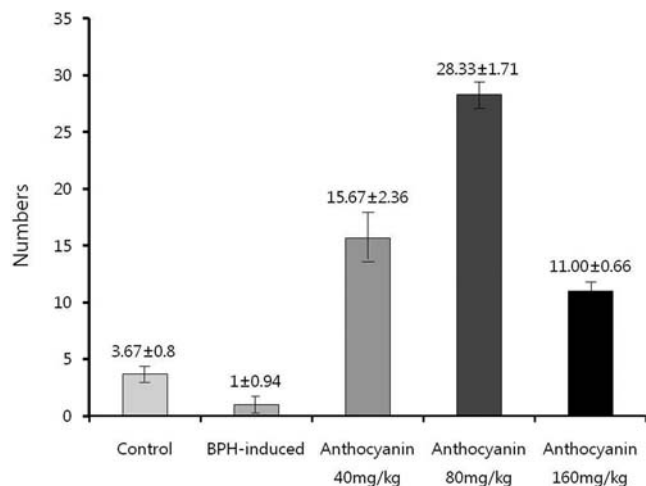


Figure 5. Mean numbers of positive TUNEL cells in the control group, BPH-induced group, and anthocyanin-administered groups. The mean numbers were higher in the anthocyanin-administered groups than in the control group or BPH-induced group, especially in the group administered 80 mg/kg anthocyanin.

observed in both intrinsic (mitochondrial) and extrinsic (FAS) pathways (20, 21). In addition, anthocyanin has been shown to have anti-inflammatory effects by down-regulating the inflammatory proteins nuclear factor- κ B (NF- κ B) and cyclooxygenase-2 (COX-2) (20, 23) and to have antiangiogenesis effects by suppressing the expression of vascular endothelial growth factor (VEGF) and VEGF receptor antiangiogenesis (24). It was found that anthocyanin has diverse antitoxic and antineoplastic effects, and it could be summarized that such effects are achieved by the direct removal of reactive oxygen species, augmentation of the ability of cells to absorb oxygen-radicals, stimulation of the expression of phase II detoxification enzymes, reduced synthesis of oxygen adducts in DNA, reduction of lipid peroxidation, suppression of mutagenesis by environmental toxins and carcinogens, and suppression of cell proliferation.

We hypothesize that the suppression of prostate proliferation as well as the reduction of prostate volume observed in response to the administration of anthocyanin was due to antiproliferative reactions of anthocyanin that inhibited various cell cycle control proteins at different cell cycle stages. The increased number of apoptotic bodies within prostate tissues from rats administered anthocyanin could be considered to be the effect of the induction of apoptosis by the antioxidant reaction of anthocyanin. Together with the antiproliferative activity of anthocyanin, the antioxidant activity resulted in suppressing the proliferation of prostate cells and reducing prostate volume.

We found that the reduction of prostate weight and increased apoptosis were not necessarily proportional to the increase in the dose of anthocyanin. This result agrees with observations made by Salganik (25) showing that whereas reactive oxygen species are an important trigger, mediator, and executioner in the antimicrobial phagocytosis of bacteria and cancer cells (26–30), detoxification by cytochrome P-450 complex (31), and apoptosis induction (32–35), these protective functions could be inhibited by an overdose of antioxidants. It was further speculated that in patients with high baseline levels of reactive oxygen species, supplementation of exogenous antioxidants would be effective in protection against oxidative injury, and in patients with low levels of reactive oxygen species, normal protective function by reactive oxygen species could be inhibited by an overdose of exogenous antioxidant supplementation (25). This could help to

explain our finding that a lower rate of apoptosis was observed in the rats that received the highest dose of anthocyanin.

In our study, we estimated the antiproliferative activity and apoptosis induction resulting from the antioxidant reaction of anthocyanin by comparing prostate weight and the number of apoptotic bodies within prostate tissues observed after the administration of anthocyanin. However, the levels of oxidation as well as antioxidant within the prostate in response to the administration of anthocyanin were not measured quantitatively. Further experimentation is required to prove that the antioxidant reaction of anthocyanin induced the apoptosis of prostate cells. A better understanding of the antioxidant properties of anthocyanin may lead to a clinical application of the compound that could be effective in preventing or treating BPH.

In conclusion, in rats with induced prostatic hyperplasia, administration of anthocyanin resulted in a reduction in prostate weight and an increase in apoptosis. We believe that the administration of anthocyanin may be effective in BPH, and we suggest that our experiment could be the basis for the clinical application of anthocyanin.

LITERATURE CITED

- (1) De La Fuente, M. Effects of antioxidants on immune system ageing. *Eur. J. Clin. Nutr.* **2002**, *56* (3), S5–S8.
- (2) Harman, D. Aging: a theory based on free radical and radiation chemistry. *J. Gerontol.* **1957**, *2*, 298–300.
- (3) Finkel, T.; Holbrook, N. J. Oxidants, oxidative stress and the biology of aging. *Nature* **2000**, *408*, 239–247.
- (4) Roehrborn, C. G.; McConnell, J. D. Etiology, pathophysiology, epidemiology, and natural history of benign prostatic hyperplasia. In *Campbell's Urology*, 8th ed.; Walsh, P. C., Retik, A. B., Wein, A. W., Vaugh, E., Eds.; Lipincott Williams and Wilkins: Philadelphia, PA, 2002; Vol.2, pp 1297–1336.
- (5) Isaacs, J.; Coffey, D. S. Etiology and disease process of benign prostatic hyperplasia. *Prostate* **1987**, *2* (suppl), 33–50.
- (6) Coffey, D. S.; Walsh, P. C. Clinical and experimental studies of benign prostatic hyperplasia. *Urol. Clin. North Am.* **1990**, *17*, 461–475.
- (7) Kowald, A.; Kirkwood, T. B. Accumulation of defective mitochondria through delayed degradation of damaged organelles and its possible role in ageing of post-mitotic and dividing cells. *J. Theor. Biol.* **2000**, *202*, 145–160.
- (8) Francis, F. J. Food colorants: anthocyanins. *Crit. Rev. Food Sci. Nutr.* **1989**, *28*, 273–314.
- (9) Harborne, J. B.; Wiliam, C. A. Advances in flavonoid research since 1992. *Phytochemistry* **2000**, *55*, 481–504.
- (10) Sastre, J.; Pallardo, F. V.; Garcia de la Asuncion, J.; Vina, J. Mitochondria, oxidative stress and aging. *Free Radical Res.* **2000**, *32*, 189–98.
- (11) Rahman, K. Studies on free radicals, antioxidants, and co-factors. *Clin. Interventions Aging* **2007**, *2* (2), 219–236.
- (12) Wang, S. Y.; Jiao, H. Scavenging capacity of berry crops on superoxide radicals, hydrogen peroxide, hydroxyl radicals, and singlet oxygen. *J. Agric. Food Chem.* **2000**, *48*, 5677–5684.
- (13) Shih, P. H.; Yeh, C. T.; Yen, G. C. Effects of anthocyanidin on the inhibition of proliferation and induction of apoptosis in human gastric adenocarcinoma cells. *Food Chem. Toxicol.* **2005**, *55*, 1557–1566.
- (14) Rodrigo, K. A.; Rawal, Y.; Renner, R. J.; Schwartz, S. J.; Tian, Q.; Larsen, R. E.; Mallery, S. R. Suppression of the tumorigenic phenotype in human oral squamous cell carcinoma cells by an ethanol extract derived from freeze-dried black raspberries. *Nutr. Cancer* **2006**, *54*, 58–68.
- (15) Seeram, N. P.; Adams, L. S.; Zhang, Y.; Lee, R.; Sand, D.; Scheuller, H. S.; Heber, D. Blackberry, black raspberry, blueberry, cranberry, red raspberry, and strawberry extracts inhibit growth and stimulate apoptosis of human cancer cells in vitro. *J. Agric. Food Chem.* **2006**, *54*, 9329–9339.
- (16) Chen, P. N.; Chu, S. C.; Chiou, H. L.; Chiang, C. L.; Yang, S. F.; Hsieh, Y. S. Cyanidin 3-glucoside and peonidin 3-glucoside inhibit tumor cell growth and induce apoptosis in vitro and suppress tumor growth in vivo. *Nutr. Cancer* **2005**, *53*, 232–243.

- (17) Reddy, M. K.; Alexander-Lindo, R. L.; Nair, M. G. Relative inhibition of lipid peroxidation, cyclooxygenase enzymes, and human tumor cell proliferation by natural food colors. *J. Agric. Food Chem.* **2005**, *53*, 9268–9273.
- (18) Zhang, Y.; Seeram, N. P.; Lee, R.; Feng, L.; Heber, D. Isolation and identification of strawberry phenolics with antioxidant and human cancer cell antiproliferative properties. *J. Agric. Food Chem.* **2008**, *56*, 670–675.
- (19) Zhang, Y.; Vareed, S. K.; Nair, M. G. Human tumor cell growth inhibition by nontoxic anthocyanidins, the pigments in fruits and vegetables. *Life Sci.* **2005**, *76*, 1465–1472.
- (20) Olsson, M. E.; Gustavsson, K. E.; Andersson, S.; Nilsson, A.; Duan, R. D. Inhibition of cancer cell proliferation in vitro by fruit and berry extracts and correlations with antioxidant levels. *J. Agric. Food Chem.* **2004**, *52*, 7264–7271.
- (21) Afaq, F.; Syed, D. N.; Malik, A.; Hadi, N.; Sarfaraz, S.; Kweon, M. H.; Khan, N.; Zaid, M. A.; Mukhtar, H. Delphinidin, an anthocyanidin in pigmented fruits and vegetables, protects human HaCaT keratinocytes and mouse skin against UVB-mediated oxidative stress and apoptosis. *J. Invest. Dermatol.* **2007**, *127*, 222–232.
- (22) Reddivari, L.; Vanamala, J.; Chintharlapalli, S.; Safe, S. H.; Miller, J. C., Jr. Anthocyanin fraction from potato extracts is cytotoxic to prostate cancer cells through activation of caspase-dependent and caspase independent pathways. *Carcinogenesis* **2007**, *28*, 2227–2235.
- (23) Martin, S.; Giannone, G.; Andriantsitohaina, R.; Martinez, M. C. Delphinidin, an active compound of red wine, inhibits endothelial cell apoptosis via nitric oxide pathway and regulation of calcium homeostasis. *Br. J. Pharmacol.* **2003**, *139*, 1095–1102.
- (24) Bagchi, D.; Sen, C. K.; Bagchi, M.; Atalay, M. Anti-angiogenic, antioxidant, and anti-carcinogenic properties of a novel anthocyanin-rich berry extract formula. *Biochemistry (Moscow)* **2004**, *69*, 75–80.
- (25) Salganik, R. I. The benefits and hazards of antioxidants: controlling apoptosis and other protective mechanisms in cancer patients and the human population. *J. Am. Coll. Nutr.* **2001**, *20* (5), 464–472.
- (26) Halliwell, B.; Gutteridge, J. M. C. *Free Radicals in Biology and Medicine*, 3rd ed.; Oxford University Press: Oxford, U.K., 1999; p 41.
- (27) Babior, B. M. Oxygen-dependent microbial killing by phagocytes. *N. Engl. J. Med.* **1978**, *298*, 721–725.
- (28) Alexander, P. Can antioxidants facilitate cancer induction? Oxidation reactions involved in host-mediated destruction of cancer cells. In *Radioprotectors and Anticarcinogenes*; Simic, M. G., Ed.; Academic Press: New York, 1983; pp 575–584.
- (29) Rossi, F.; Zatti, M. Biochemical aspects of phagocytosis in polymorphonuclear leucocytes. NADH and NADPH oxidation by the granules of resting and phagocytizing cells. *Experientia* **1980**, *20*, 21–27.
- (30) Cedro, K.; Klosiewicz-Wasek, B.; Wasek, W. Inhibitory effect of vitamins C and E on the oxygen free radical production in human polymorphonuclear leucocytes. *Eur. J. Clin. Invest.* **1994**, *24*, 316–319.
- (31) Ghosh, M. K.; Mukhopadhyay, M.; Chatterjee, I. B. NADPH-initiated P450-dependent free-iron-dependent microsomal lipid peroxidation: specific prevention by ascorbic acid. *Mol. Cell. Biochem.* **1997**, *166*, 35–44.
- (32) Verhaegen, S.; Adrian, J.; McGovan, J.; Brophy, A. R.; Fernandes, R. S.; Gotter, T. G. Inhibition of apoptosis by antioxidants in the human HL-60 leukemia cell line. *Biochem. Pharmacol.* **1995**, *40*, 1021–1029.
- (33) McGovan, A. J.; Fernandes, R. S.; Samali, A. A.; Cotter, T. G. Antioxidants and apoptosis. *Biochem. Soc. Trans.* **1996**, *24*, 229–233.
- (34) Labriola, D.; Livingston, R. Possible interaction between dietary antioxidants and chemotherapy. *Oncology* **1999**, *13*, 1003–1012.
- (35) Salganik, R. I.; Sivashinskiy, M. S.; Lopaczinsky, W.; Gulij, M.; Veisman, A.; Bokovanov, V. E.; Zeisel, S. H. Controlling the anti-cancer activity of cisplatin by changing the redox state of MCF-7 breast cancer cells. *Carcinogenesis* **2001**.

Received for review July 13, 2010. Revised manuscript received October 29, 2010. Accepted November 3, 2010. This research was supported by the Biogreen21 Program (Code PJ007186), Rural Development Administration, Suwon, Republic of Korea.